

CLINICAL NOTE

IMPACT OF ETHNIC HABITS ON DEFECOGRAPHIC MEASUREMENTS

Saeed Rad MD

Department of Radiology, Tabriz University of Medical Sciences, Tabriz, Iran

Background- Defecography, along with other radiologic modalities, can be used to evaluate rectal abnormalities such as functional disorders of the rectum. It appears that ethnic habits can influence the evacuative function of the rectum. The main goal of this study was to compare Iranian and European habits of bowel evacuation on defecographic measurements.

Methods- Thirty Iranian patients (21 male, 9 female) referred for barium enema were enrolled in the study. The patients were instructed to defecate using two types of toilet: an unraised, ground-level style (common in Iran), and a bowl with attached tank style (common in Western countries). Radiographs were taken of each patient while defecating into both types of toilet, during which the anorectal angle and other defecographic indices were measured.

Results- Use of the Iranian-style toilet yielded a much wider anorectal angle, and a larger distance between the perineum and the horizontal plane of the pelvic floor than the European style. Bowel evacuation was also more complete using the Iranian-style toilet.

Conclusion- Use of the Iranian-style toilet seems to be more a more comfortable and efficient method of bowel evacuation than the European style. Further studies are needed to ascertain the optimal approximation of the measurements to standard height of toilets for ordinary use.

Keywords • defecography • ethnic • toilet • anorectal angle

Introduction

Dyschezia and fecal incontinence have always been important for human beings. Several methods have been used during the past 10 years to examine anal sphincter state in the management of fecal incontinence, which include clinical or clinico-physiologic modalities like manometry¹, electromyography² and neuro-muscular studies. The mostly used imaging techniques include: endorectal³ or endovaginal⁴ ultrasonography, computed tomographic scanning (CT), magnetic resonance imaging (MRI)⁵ and plain or dynamic techniques like MR fluoroscopy⁶ and other multidisciplinary imaging. Evacuatory proctography⁶⁻⁸ is highly reliable and accurate in the diagnosis and management of fecal incontinence,

and is a frequently used technique in radiology. Rectography and defecography are alternative terminologies for proctography.^{9,10} The aim of the present study was to compare routine postures taken by persons using the European-style bowl and tank toilet (commode) common in Western countries versus the type common in Iran, in which the user squats during defecation. We also aimed to evaluate the influence of the posture on the value of these measurements.

Materials and Methods

Thirty patients (21 male, 9 female) from 11 to 75 years of age (mean, 45 years), who were referred for barium enema, were enrolled in the study. The patients had neither dyschezia nor other kinds of rectal disorders.

The patients were instructed to defecate in two different positions. The first radiograph was taken

• **Correspondence:** S.Rad MD, Radiology Center of Dr. Rad, 17 Shahrivar Avenue, Tabriz 51379, Iran. Fax: +98-411-3445591.

Impact of Ethnic Habits on Defecographic Measurements

during the course of bowel evacuation by patients using an Iranian-style toilet. At an appropriate time later on in the same day, a radiograph was taken from the same patients using a European-style toilet. The patients reported having normal bowel movements and could evacuate their bowels for the second time. The anorectal angle, distance between perineum and the pelvic floor, and ease and completeness of evacuation in the two different positions were evaluated (Figure).

Results

The anorectal angle was much wider in patients using the Iranian method (average, 132°) than the European one (average, 92°); sometimes, the angle disappeared entirely in the squatting position. The distance between the perineum and the horizontal plane of the pelvic floor was greater in the Iranian-style toilet than the European one (8.4 cm vs 6.6 cm).

Bowel evacuation was complete in all subjects accustomed to the Iranian habit, but they reported incomplete evacuation using the European-style toilet. They also found the ground-level Iranian-style toilet more physically comfortable to use than the raised style. With the Iranian method, puborectalis relaxation occurred easily and straight-

tening of the rectum and anal canal facilitated evacuation. The anorectal angle became wide open and no folding was noticed in the terminal rectum. As the anal canal becomes straight and in direct continuation with the rectum, rectal mucosal prolapse can easily occur. By contrast, while using the European toilet, a remarkable folding was created in the terminal rectum predisposing it to rectocele formation, and puborectalis relaxation was incomplete.

In our target population, there were no subjects who were accustomed to the European-style toilets, which would limit the generalizations drawn from this study.

Discussion

There have been intensive studies in the assessment of defecatory function biomedically, anatomically and physiologically. Anal tonometry,¹¹ pelvic floor myography,¹² segmental colonic transit time,¹³ electromyography and cineradiography,¹⁴ scintigraphic defecography,¹⁵ defecography and peritoneography,¹⁶ and manometry alone¹⁷ or combined with other modalities such as electromyography are all satisfactory methods; however, imaging has made a major contribution to the study of the act of defecation.

Some modalities including real-time ultrasonography¹⁸ and endoscopic sonography (endo-rectal²⁰ or endovaginal²¹) have been implemented to study the anal sphincter.¹⁹ Static²² or dynamic²³ CT scan and MRI have been used by others, but evacuating proctography or defecography seems to have the best advantage among all of the above-mentioned methods. The defecogram has the capability of directly showing the entire effective process. The concomitant use of image recording by videotaping²⁴ or cinematography²⁵ will permit repeated study at serial timepoints, and can accurately define the underlying disorder; e.g., what to perform in order to study deglutition. Multifactorial defecatory function has to be studied from the structural point of view. Testing puborectalis or sling muscle coordination, which causes opening of the pelvic outlet, and examining the integrity of the external and internal anal sphincters is necessary in this regard. Neuromuscular function must also be evaluated. Any dysynergia such as levator ani spasm or puborectalis syndrome,²⁵ a tight anal sphincter due to causes such as anal fissure or perianal fistula may prevent satisfactory bowel emptying. The

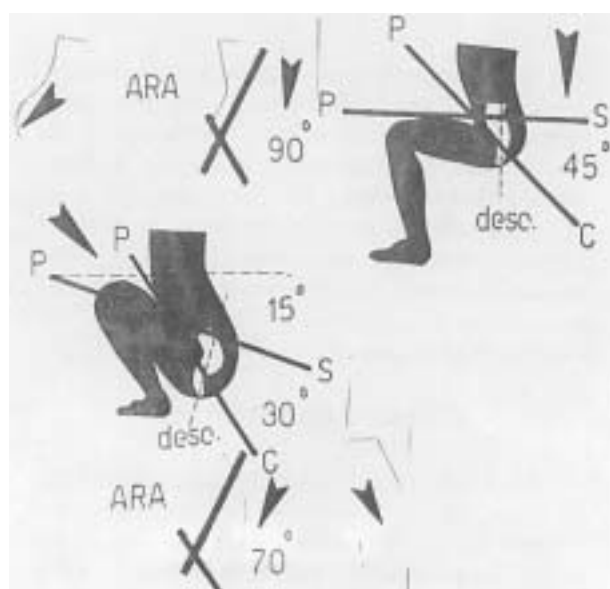


Figure. Defecograph showing the anorectal angle as measured in two different positions of bowel evacuation.

choice of imaging modality should be tailored according to the previously mentioned factors. In my opinion, as a radiologist, defecography has the potential of determining the anatomic and functional defects simultaneously and can be considered the technique of choice.

It appears that Iranians are more comfortable using an Iranian-style toilet than a European-style one. One of the most significant limitations of the present study was having to select individuals who were not accustomed to European toilets. When someone is used to using a special type of toilet, suddenly changing his or her habit puts severe psychologic stress on the person and evacuation may not be complete in the new method. In addition, anatomic structures involving the process of bowel evacuation adapt themselves with an individual's habit over time and somehow change according to the position of defecation. Additional studies are recommended to determine the optimal height of toilets for the most effective perineal structure for the process of evacuation. In order to eliminate any bias resulting from changing the anatomy of the evacuative apparatus according to habits with time, such evaluations can be accomplished on artificial simulated models with which one can estimate the optimal height and shape of toilets for ordinary use.

References

- 1 Rao SS. Manometric evaluation of constipation-Part I. *Gastroenterologist*. 1996; **4**: 145-54.
- 2 Kuijpers HC. Application of the colorectal laboratory in diagnosis and treatment of functional constipation. *Dis Colon Rectum*. 1990; **33**: 35-9.
- 3 Nielsen MB, Rasmussen OO, Pedersen JF, et al. Anal endosonographic findings in patients with obstructed defecation. *Acta Radiol*. 1993; **34**: 35-8.
- 4 Rao SS, Sun WM. Current techniques of assessing defecation dynamics. *Dig Dis*. 1997; **1**: 64-77.
- 5 Delemarre JB, Kruyt RH, Doornbos J, et al. Anterior rectocele: assessment with radiographic defecography, dynamic magnetic resonance imaging and physical examination. *Dis Colon Rectum*. 1994; **37**: 249-59.
- 6 Schoenenberger AW, Debatin JF, Guldenschuh I, et al. Dynamic MR defecography with a superconducting open configuration MR system. *Radiology*. 1998; **206**: 641-6.
- 7 Ginai AZ. Evacuation proctography (defecography): a new seat and method of examination. *Clin Radiol*. 1990; **42**: 214-6.
- 8 Freimanis MG, Wald A, Caruana B, Bauman DH. Evacuation proctography in normal volunteers. *Invest Radiol*. 1991; **26**: 581-5.
- 9 Kelvin FM, Maglinte DD, Benson JT, Pittman JS. Re: the role of defecography in clinical practice. *Abdomen Imaging*. 1995; **20**: 279-80.
- 10 Goei R. Defecography: principles of technique and interpretation. *Radiologe*. 1993; **33**: 356-60.
- 11 Saraiva MM, Saraiva AM. Anal tonometry: a quick method of anal manometry. *Dis Colon Rectum*. 1991; **34**: 396-400.
- 12 Parks TG. The usefulness of tests in anorectal disease. *World J Surg*. 1992; **16**: 804-10.
- 13 Karasick S, Ehrlich SM. Is constipation a disorder of defecation or impaired motility? Distinction based on defecography and colonic transit studies. *AJR Am J Roentgenol*. 1996; **166**: 63-6.
- 14 Johansson C, Ihre T, Holmstrom B, et al. A combined electromyographic and cineradiologic investigation in patients with defecation disorders. *Dis Colon Rectum*. 1990; **33**: 1009-13.
- 15 Huchinson R, Mostafa AB, Grant EA, et al. Scintigraphic defecography: quantitative and dynamic assessment of anorectal function. *Dis Colon Rectum*. 1993; **36**: 1132-8.
- 16 Bremmer S, Ahlback SO, Uden R, Mellaren A. Simultaneous defecography and peritoneography in defecation disorders. *Dis Colon Rectum*. 1995; **38**: 969-73.
- 17 Rao SS. Manometric evaluation of defecation disorders: part II. Fecal incontinence. *Gastroenterologist*. 1997; **5**: 99-111.
- 18 Stewart LK, Wilson SR. Transvaginal sonography of the anal sphincter: reliable or not? *AJR Am J Roentgenol*. 1999; **173**: 179-85.
- 19 Rociu E, Stoker J, Eijkemans MJ, et al. Fecal incontinence: endoanal ultrasonography versus endoanal MR imaging. *Radiology*. 1999; **212**: 453-8.
- 20 Kelvin FM, Hale DS, Maglinte DD, et al. Female pelvic organ prolapse: diagnostic contribution of dynamic cystoproctography and comparison with physical examination. *AJR Am J Roentgenol*. 1999; **173**: 31-7.
- 21 Hock D, Lombard R, Jehaes C, et al. Colpocystodefecography. *Dis Colon Rectum*. 1993; **36**: 1015-21.
- 22 Kruyt RH, Delemarre JB, Doornbos J, et al. Normal anorectum: dynamic MR imaging anatomy. *Radiology*. 1991; **179**: 159-63.
- 23 Piloni V. Functional radiology of the anorectal region. *Ital J Gastroenterol*. 1991; **23**: 25-9.
- 24 Vanbekewoort D, Van Hoe L, Oyen R, et al. Pelvic floor descent in female: comparative study of colpocystodefecography and dynamic fast MR imaging. *J Magn Reson Imaging*. 1999; **9**: 373-7.
- 25 Jorge JM, Wexner SD, Ger GC, et al. Cinedefecography and electromyography in the diagnosis of nonrelaxing puborectalis syndrome. *Dis Colon Rectum*. 1993; **36**: 668-76.